

Restoration of severely mutilated primary incisors using "omega shaped wire" as intracanal post-clinical technique -A CASE REPORT.



*Dr. Rashmi .C.
PG STUDENT*



*Dr.Sathyajith Naik.
Professor*



*Dr. K. K. Shashibhushan.
Professor*



*Dr.V .V. Subba Reddy Principal,
Professor and Head.*

Department of Pedodontics

INTRODUCTION

The restoration of severely carious primary anterior teeth is a challenge to the pediatric dentist, and maintenance of the primary dentition in a non pathologic and healthy condition is important for the well being of the child as well for proper mastication and prevention of aberrant habits such as tongue thrust.

The esthetic restoration of severely mutilated primary anterior teeth has for a long time been a challenge to the pediatric dentist not only because of available materials and techniques, but also because the children who require these restorations are usually among the youngest and least manageable group of patients. In addition to management problems, there are a number of technical problems with respect to the restoring of the primary incisor teeth. They have short and narrow crowns, only a small surface for bonding; a pulp chamber that is large relative to the crown size and enamel that is inheritantly difficult to acid etch due to its aprismatic nature.¹

In many cases, the destruction of the tooth structure involves the entire crown, leaving just the root and hence, only dentine for bonding of the restorative materials. Endodontic treatment associated with the use of intracanal retainers is necessary prior to coronal restoration. After placement of intracanal retainers, the remaining coronal structure can be restored with direct or indirect techniques.²

This case report describes the restoration of grossly decayed primary maxillary incisors using "omega shaped stainless steel wire of 0.6mm (23 gauze) thickness.

Purpose: To present an alternative functional and esthetic restorative technique for primary

CASE REPORT:

A 4 year old boy reported to the Department of Pedodontics and Preventive Dentistry with the history of pain in relation to upper anterior teeth. On examination the four upper incisors were grossly destructed with only the root stumps left. In addition the posterior teeth were all affected with caries.

TREATMENT PROTOCOL: The following treatment protocol was followed to restore the anterior teeth and posterior teeth.

1. Caries removal and subsequent restoration of the carious posterior teeth with GIC.
2. Pulpectomy of the maxillary incisors. The maxillary incisors were endodontically treated

3. Preparation of the canal. Canals were shaped and prepared to 1/3 of their length to receive intracanal retainer.
4. Construction of the intracanal retainer (Omega shape wire extension):
The wire extension, used for ancillary retention and support, was made from 1.5 cm length of 0.6 mm round orthodontic stainless steel wire which was bent using universal orthodontic pliers, into an omega shape wire extension as shown in figure 2. The pulpal ends extended approximately 3mm into the root canal so as to increase the overall retention of the wire. The incisal end of the loop projected 2-3 mm above
5. Placement of omega wire extension
Omega shape wire extension is posted into the root canals using autocure glass ionomer cement as shown in the figure 4.
6. Restoration of the crown with direct composite.
Incisal end of omega loop received a layer of opaque material and reconstruction and shaping of the crown over the incisal loop of the wire was carried out with additional composite which was cured layer by layer until the final reconstruction was achieved. After checking the occlusion, final finishing and polishing of the restoration was performed with soflex discs (figure 5).

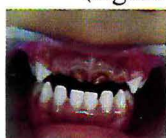

Fig 1: PRE-OP PICTURE
INTRA ORAL.



FIG 2: OMEGA EXTENSION

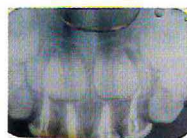

FIG 3: POST OP INTRAORAL
PERIAPICAL RADIOGRAPH.

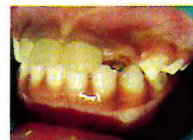

Fig 4: OMEGA EXTENSION PLACED
INSIDE THE CANAL

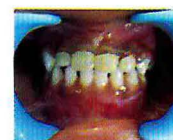

Fig 5: POST OP PICTURE OF
FINAL RESTORED ANTERIOR

Discussion:

The successful restoration of badly mutilated primary anterior teeth in preschool children is a challenging task. The failure rate of restorations is high due to the absence of sufficient tooth structure to support the restoration in addition to the poor adhesion of the primary teeth compared to permanent teeth.

A simple yet effective technique to overcome these failures has been described in which a custom made omega shape wire extension was placed in the space of the pulp chamber and entrance of the root canal with the projecting portion the loop being used for retention of the coronal restoration. The wire did not appear to cause any internal stresses in the root probably because it was engaged in the build up material. As the teeth were pulpally treated, it was possible to inject the build up material into the remaining part of the pulp chamber and in the cervical region of the root canal where it supported the coronal restoration.³

The described technique achieved excellent cosmetic results, furthermore it was simple and quick to execute. However, it was relatively technique sensitive in that it required a degree of patient co-operation. The parents of the child, who was treated, reported an improvement in psychological behavior of the child and felt that the lifestyle of the child has improved.

Conclusion:

1. This "omega extension" increased the retentive properties of the remaining tooth structure
2. This technique achieved excellent cosmetic results.
3. The technique was easy to master.
4. Periodic reviews are necessary for the detection and repair of minor fractures.

References

1. A. Mortada, N.M. King. A simplified technique for the restoration of severely mutilated primary anterior teeth. *Journal of pediatric dentistry* 2004;28(3):187-192.
2. Marria Tubolla Wanderley, Sylvia Lavinia Martini Ferreira. Primary anterior tooth restoration using posts with macroretentive elements. *Quintessence International* 30(6):432-436.
3. C.Motitsuki, L.Santos-Pinto and EMA Giro. Restoration of severely decayed primary incisors using Indirect composite resin restoration technique. *International journal of paediatric dentistry* 2005;15:282-286.

Oral Hygiene Day



College Day Celebration




With Best Compliments From



NIKHIL EQUIPMENTS PVT. LTD

WE PROVIDE TOTAL SOLUTIONS IN :

- Compactors (Mobile Racks)- Storage Systems
- Multitier Compactors with Mezzanine.
- Automated Vertical Carousels.
- Stacker Crane with powered Turn Table and Telescopic Mast
- Very Narrow Aisle (VNA) type Stacker Crane with Sliding Fork Carrier & Swiveling Forks for very narrow aisles.
- Integrated Rack Supported Warehouse.



OUR CONTACT DETAILS :

Mr. Dilip Kanetkar, Managing Director,
Mr. Dutta Damle, Director,
Mr. H Dinesh Pai, Associate, Marketing & Customer Relations

Regd. & Head Office :

Tushar Residency, Plot No. 99, S. No. 95, Bhusari Colony, Paud Road, Kothrud, Pune - 411 038. INDIA.
Phone : 020 - 25286640 / 41 Fax : 020 - 25286642 Mobile : Kanetkar +91 98220 35002,
Damle +91 98223 00616 E-mail : md@nikhilequipments.com

Associate Office in Belgaum :

731/A, Plot No. 3, Opp. H.P. Building, Angol Extension 'C' Scheme, Tilakwadi, Belgaum -590 006.
Phone : 0831-244 1738 Cell : +91-98451 46148 E-mail : dinpaih@yahoo.com

Contact Digitals:- 9886757307

You name it, We store it