

Cephalometric Evaluation of Stability of Airway Changes Obtained with Twin-block Therapy

Garima Gupta¹, Mala R Manohar²

ABSTRACT

Background: Mandibular retrognathism or functional mandibular retrusion is commonly associated with the reduced pharyngeal airway. Functional appliances that are used to treat mandibular retrusion have been found to improve airway dimensions. However, this improvement in the airway has never been assessed in the long-term. Therefore, the purpose of this study was to assess the effects of standard twin-block appliance on pharyngeal airway space in subjects with skeletal class-II pattern and the maintenance of changes achieved after debonding.

Materials and methods: Twenty-five subjects (14 females and 11 males) in the age-group of 10–14 (mean 12.08 ± 0.91) underwent treatment of a class II division 1 malocclusion via standard twin-block appliance followed by fixed orthodontic therapy. Pre-treatment (T1), post-twin block (T2), and post-fixed appliance (T3) lateral cephalograms were taken and skeletal and soft tissue landmarks were hand-traced. A pairwise comparison was used to assess whether there were any significant differences in the cephalometric variables of the upper and lower pharyngeal airway between each phase of treatment (T1, T2, T3).

Results: There was a significant increase in sagittal dimensions of upper and lower pharyngeal space with a mean increase of 1.34 and 1.26 mm, respectively, following twin-block therapy. There was a significant increase in upper pharyngeal space from pre-treatment till the end of the fixed appliance phase ($p < 0.003$) and the change in lower pharyngeal space from pre-treatment till the end of the fixed appliance phase was non-significant ($p = 0.13$).

Conclusion: Correction of mandibular retrusion in class II malocclusion subjects by twin-block therapy increased the sagittal dimension of the upper and lower pharyngeal space. This significant improvement in the upper pharyngeal space was maintained till the end of fixed orthodontic treatment. However, the improvement in the lower pharyngeal space was found to be unstable post-debonding.

Keywords: Long-term stability, Lower airway space, Standard twin-block appliance, Upper airway space.

CODS Journal of Dentistry (2020): 10.5005/jp-journals-10063-0063

INTRODUCTION

Altered morphology of different orofacial structures like shortened mandible, enlarged adenoids, tonsillar hypertrophy, and macroglossia play a vital role in reducing the airflow through the nasopharynx and the oropharynx. In addition, a retro-positioned mandible or maxilla can push an enlarged tongue posteriorly to impinge on the retropharyngeal area resulting in breathing difficulties.¹

A growing child diagnosed with a class II skeletal pattern due to mandibular micrognathism or retrognathism is ideally treated with functional orthopedic appliances, whereas orthognathic surgeries to advance the mandible is the only viable option of correcting a skeletal deformity in a non-growing adult.

Robin was the first to use an intraoral appliance to bring the lower jaw forward in newborns with mandibular deficiency, thereby preventing posterior relocation of the tongue during sleep and the occurrence of oropharyngeal collapse.² This concept of positioning the jaw forward to stimulate mandibular growth led to new areas of research.

Growth-modifying functional appliances can redirect the mandibular growth in a favorable direction, markedly augment the facial esthetics and prevent oropharyngeal collapse by modifying the posterior position of the tongue.^{3,4}

Previous studies have reported significant improvement in few parameters of pharyngeal dimensions with multiple growth-modifying appliances but very few studies have evaluated the stability of this effect on the nasopharyngeal area and pharyngeal airway dimensions over time.

^{1,2}Department of Orthodontics, College of Dental Sciences, Davangere, Karnataka, India

Corresponding Author: Garima Gupta, Department of Orthodontics, College of Dental Sciences, Davangere, Karnataka, India, Phone: +91 8962823172, e-mail: garimagupta010@gmail.com

How to cite this article: Gupta G, Manohar MR. Cephalometric Evaluation of Stability of Airway Changes Obtained with Twin-block Therapy. CODS J Dent 2020;12(1):2–6.

Source of support: Nil

Conflict of interest: None

The study aimed to assess the upper pharyngeal airway (UA) and lower pharyngeal airway (LA) in subjects with class II malocclusion undergoing functional appliance therapy with standard twin-block appliance and subsequent fixed orthodontic treatment.

Additionally, this study was used to compare the changes in the airway from pre-treatment to post-twin block to post-fixed appliance treatment.

MATERIALS AND METHODS

Lateral cephalograms of 25 patients treated with twin block therapy were taken from record collection at the institute. Patients in cervical vertebral maturity index (CVMI) 3 and 4 with Angle's class II div 1 malocclusion having normal maxilla

and retrognathic mandible with A point, nasion, B point (ANB) $>4^\circ$ were included in this study. Patients with any history of respiratory illness, previous orthodontic treatment or orthopedic treatment, abnormal phenotypes (clefts or syndromes), and Angles class II malocclusion due to prognathic maxilla were excluded from the study.

All patients were fitted with the standard twin-block appliance (with appropriate sagittal advancement). The orthopedic phase (functional appliance therapy) was continued till the required sagittal advancement was attained, followed by a retention phase of 6 months. This was followed by fixed appliance therapy. The mean total treatment duration was 25.5 ± 2.4 months. All cephalometric radiographs were obtained before the initiation of treatment, at the end of a twin-block phase, and at the end of fixed orthodontic treatment with the Sirona Galileos imaging unit. The digital lateral cephalograms were traced manually and the linear measurements were recorded (Fig. 1).

Pharyngeal Airway Analysis

The McNamara's pharyngeal airway analysis was performed to obtain the routine linear measurements of the UA and LA. Upper pharyngeal width is measured from a point on the posterior outline of the soft palate to the nearest point on the pharyngeal wall. This measurement is taken on the anterior half of the soft palate. The LA is measured from the point of intersection of the posterior border of the tongue and the inferior border of the mandible to the closest point on the posterior pharyngeal wall.⁵

Statistical Analysis

Data comprising of linear upper and lower pharyngeal space measurements were evaluated with the pairwise comparison test and repeated one-way analysis of variance (ANOVA) was used for the comparison of airway dimension changes over time. *Post hoc* test (Bonferroni test) was used for multiple comparisons of dimensions between different time intervals. A probability (p value) of <0.05 was considered statistically significant. All data were evaluated using statistical software (IBM SPSS V23.0, IBM Corp., Armonk, NY, USA).

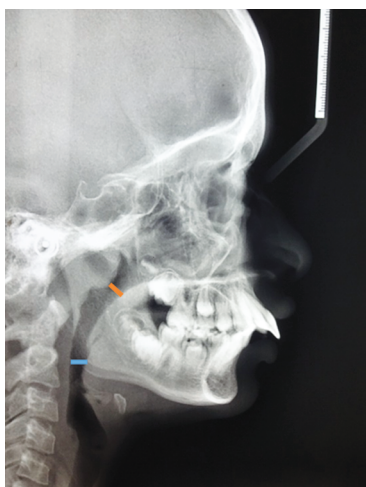

Fig. 1: Upper pharyngeal space marked in orange color. Lower pharyngeal space marked in blue color

RESULTS

The mean values and the standard deviations for the UA and LA in the studied population at pre-treatment (T1), post-twin block (T2), and post-fixed orthodontic time intervals (T3) are presented in Table 1 and Figure 2.

One-way ANOVA was used to compare the upper and lower pharyngeal space over time (T1, T2, T3). There is a significant change in the UA and LA at different time intervals as shown in Table 1. The mean increase in the UA from pre-treatment to post-twin block phase is 1.34 mm and for LA is 1.26 mm. The mean increase in the UA from post-twin block phase to post-fixed appliance phase is 0.44 mm and the mean decrease for LA from post-twin block phase to post-fixed appliance phase is 0.36 mm.

There was a highly significant increase in the LA from T1 to T2 ($p = 0.003$) and no significant difference was observed from T2 to T3 ($p = 1$) as shown in Table 2.

For the UA, there was a significant increase from T1 to T2 ($p = 0.01$) and from T2 to T3 was non-significant ($p = 1$) as shown in Table 2.

From T1 to T3, in the lower pharyngeal measurement, the change was not significant ($p = 0.13$). The change in the UA from T1 to T3 was highly significant with $p = 0.003$ (Table 3).

DISCUSSION

Mouth-breathing habit is a common finding in children in the younger age-group and is often associated with mandibular retrusion and maxillary constriction. Small pharyngeal dimensions established early in life may predispose one to sleep-disordered breathing later when subsequent soft tissue changes caused by age, obesity, or genetic background further reduce the available oropharyngeal airway.⁶ These children often show symptoms such as attention deficit disorder (ADD) which is linked to poor performance at school and nocturia. Therefore, it can only be regarded as beneficial if functional appliance treatment in children results in a permanent increase in posterior airway dimensions. Even in children with no constriction of maxilla with the presence of mouth breathing habit requires intervention by maxillary expansion which has been found to increase nasal floor volume and promote nasal breathing in these children.

Lateral cephalograms are a routine part of an orthodontic evaluation for diagnosis and treatment planning. The use of lateral cephalograms for airway analysis is an established tool.⁷ Airway dimension and tongue- and hyoid-position measurements are highly reproducible on natural-head-position cephalograms.⁸ Although three-dimensional imaging has been proven to be most accurate for the evaluation of posterior airway dimension, but the technique is not available in all centers and results in a relatively high radiation dose. For this study, only lateral cephalograms that have been taken for diagnosis and treatment planning were used and patients were not exposed to any other means of radiation.

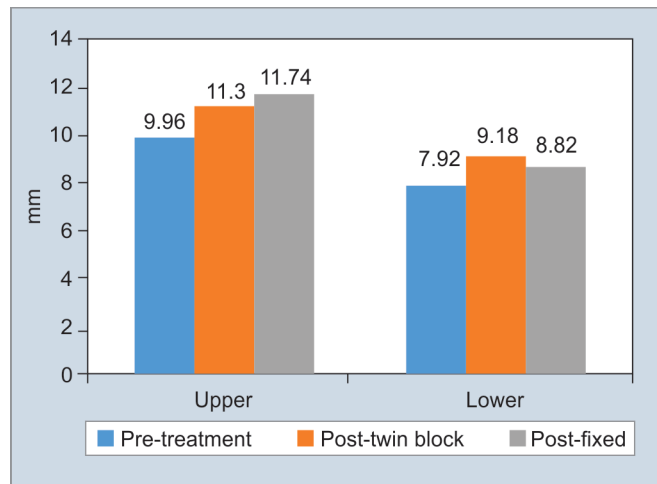
In this study, we evaluated the airway dimensions in class II subjects who have undergone standard twin-block therapy and subsequent fixed-appliance therapy at the institute. Upper and lower pharyngeal space according to McNamara analysis was measured on manually-traced lateral cephalograms at different time intervals.

The results from this study show that there was a significant increase in upper and lower pharyngeal space immediately after twin-block therapy. Overall, the upper pharyngeal space showed

Table 1: Comparison of pharyngeal space between different time intervals

Group	Stage	N	Mean	Std. deviation	F	p value
Upper	Pre-treatment	25	9.96	3.31	7.28	0.002*
	Post-twin block	25	11.30	3.07		
	Post-fixed	25	11.74	3.00		
Lower	Pre-treatment	25	7.92	2.00	4.79	0.01*
	Post-twin block	25	9.18	2.55		
	Post-fixed	25	8.82	2.85		

Repeated measures ANOVA

* $p < 0.05$ significant, $p > 0.05$ non-significant, NS**Fig. 2:** Mean and standard deviation for the upper and lower pharyngeal airway for the studied population at different time intervals (T1, T2, T3)

a highly significant increase in linear measurement from pre-treatment to the end of fixed appliance therapy, but the change in the lower pharyngeal space was not sustained till the end of fixed appliance therapy.

This is in accordance with several studies that have found an increase in oropharyngeal and nasopharyngeal airway dimensions immediately after functional appliance therapy in class II malocclusion patients treated during the peak of an adolescent growth spurt with different class II correction appliances.⁹⁻¹⁷ However, only three of these studies found that the quantified pharyngeal airway changes may be relatively stable in the long-term.^{9,10,14}

In contrast, the study by Lin et al. found no significant changes in the sagittal dimensions of the pharyngeal airway in growing retrognathic patients treated with a modified Bionator.¹³ According to Hänggi et al., improved tongue posture caused by increased genioglossal muscle tonus or other soft tissue changes may play an important role in increasing pharyngeal airway space during Fränkel-2 treatment. But none of the studies have reported long-term stability of airway changes in subjects treated with twin-block appliance.¹⁰

Jena et al. found out that in subjects with mandibular retrognathism the length of the soft palate increases as a result of the backward position of the tongue. He also found that the inclination of the soft palate was more horizontal among

subjects with mandibular retrognathism.⁴ Jena et al. also found that subjects in whom class II correction was accomplished by twin-block appliance, had improved soft palate dimensions and inclination, caused more anterior traction of the tongue away from the soft palate.¹⁶ This might be the reason for the sustenance of upper pharyngeal space changes even after fixed appliance therapy. Another possible explanation is that as the age increases, the thickness of the pharyngeal tonsil reduces, which results in a subsequent increase in the upper airway.

This study reports that although the mean lower pharyngeal space increased significantly immediately after twin block therapy, there was no significant difference in the LA space from pre-treatment to the end of fixed orthodontic treatment. This signifies that there was a relapse of the lower airway increase during the post retention phase. Almeida et al.¹⁸ and Battagel et al.¹⁹ reported that the length and height of the tongue increases after treatment with the functional appliance. Kollia and Krogstad²⁰ and Cohen and Vig²¹ reported an increase in tongue dimension with age. Yassaie et al. showed increased dimensions of the tongue even after completion of functional appliance therapy.⁹ This increase in tongue dimension may be the reason for the non-significant lower pharyngeal space results.

Another possible explanation for the lower pharyngeal space relapse could be that the hyoid bone is displaced anteriorly during active treatment with any kind of functional appliance, but reverts to its original position when the appliance is removed.^{18,19,22-25} The hyoid bone does not have any articulations with other bones and is held in position only by muscles and ligaments. It can be said that the position of the hyoid bone in rest position is affected by the balance between suprahyoid and infrahyoid muscles and any change in this balance will affect its position.

Sleep produces changes in airway physiology, which, in association with abnormal anatomy, leads to sleep-disordered breathing events and the syndrome of obstructive sleep apnea/hypopnea. Reduced dimensions of upper pharyngeal space have been linked to sleep-disordered breathing in children. In our study, it was found that the upper pharyngeal space increased significantly with twin-block therapy and the improvement was maintained till the end of fixed appliance therapy. This finding is significant and adds credibility to the treatment of class II malocclusions with retrusive mandible in growing children. The ever-ongoing debate of whether functional appliances grow mandibles may also be laid to rest if the emphasis is placed on improving the airway and hence subsequently function and followed by favorable growth. This could become a treatment modality for improving the airway in children suffering from sleep apnea.

Table 2: Pairwise comparison of pharyngeal space between different time intervals

Pharyngeal space	(I) Time	(J) Time	Mean difference (I-J)	Std. error	p value	95% Confidence interval for difference	
						Lower bound	Upper bound
Upper	Pre-treatment	Post-twin block	-1.34	0.43	0.01*	-2.45	-0.23
	Post-twin block	Post-fixed	-0.44	0.54	1.00 (NS)	-1.84	0.96
Lower	Pre-treatment	Post-twin block	-1.26	0.34	0.003*	-2.13	-0.39
	Post-twin block	Post-fixed	0.36	0.48	1.00 (NS)	-0.88	1.60

Bonferroni *post hoc* test* $p < 0.05$ significant, $p > 0.05$ non-significant, NS**Table 3:** Comparison of pharyngeal space from pre-treatment to post-fixed therapy

Pharyngeal space	(I) Time	(J) Time	Mean difference (I-J)	Std. error	p value	95% Confidence interval for difference	
						Lower bound	Upper bound
Upper	Pre-treatment	Post-fixed	-1.78	0.48	0.003*	-3.01	-0.56
Lower	Pre-treatment	Post-fixed	-0.90	0.42	0.13 (NS)	-1.99	0.19

Bonferroni *post hoc* test* $p < 0.05$ significant, $p > 0.05$ non-significant, NS

CONCLUSION

Breathing is a complex function in which oropharyngeal dimensions are only one of the factors to be considered and an increase in upper airway dimensions does not automatically imply better breathing function. The following conclusions were drawn from the study:

- Twin-block therapy lead to an increase in the sagittal dimension of the upper and lower pharyngeal space immediately post-treatment.
- This significant increase in the upper pharyngeal space was stable while, the improvement in the lower pharyngeal space was found to be unstable in the long-term.

REFERENCES

- Linder-Aronson S, Henrikson CO. Radiocephalometric analysis of anteroposterior nasopharyngeal dimensions in 6- to 12-year-old mouth breathers compared with nose breathers. *ORL* 1973;35(1):19-29. DOI: 10.1159/000275083.
- Robin P. Glossoptosis due to atresia and hypotrophy of the mandible. *Am J Dis Child* 1934;48(3):541-547. DOI: 10.1001/archpedi.1934.01960160063005.
- Ozbek MM, Memikoglu TUT, Gogen H, et al. Oropharyngeal airway dimensions and functional orthopaedic treatment in skeletal class 2 cases. *Angle Orthod* 1998;68:327-336.
- Jena AK, Singh SP, Utreja AK. Sagittal mandibular development effects on the dimensions of the awake pharyngeal airway passage. *Angle Orthod* 2010;80(6):1061-1067. DOI: 10.2319/030210-125.1.
- McNamara JA. A method of cephalometric evaluation. *Am J Orthod* 1984;86(6):449-469. DOI: 10.1016/S0002-9416(84)90352-X.
- Martin SE, Mathur R, Marshall I, et al. The effect of age, sex, obesity and posture on upper airway size. *Eur Resp J* 1997;10(9):2087-2090. DOI: 10.1183/09031936.97.10092087.
- Battagel JM, Johal A, Kotecha B. A cephalometric comparison of subjects with snoring and obstructive sleep apnea. *Eur J Orthod* 2000;22(4):353-365. DOI: 10.1093/ejo/22.4.353.
- Malkoc S, Usumez S, Nur M, et al. Reproducibility of airway dimensions and tongue and hyoid positions on lateral cephalograms. *Am J Orthod Dentofacial Orthop* 2005;128(4):513-516. DOI: 10.1016/j.ajodo.2005.05.001.
- Yassaei S, Tabatabaei Z, Ghafurifard R. Stability of pharyngeal airway dimensions: tongue and hyoid changes after treatment with a functional appliance. *Int J Orthod Milwaukee* 2012;23:9-15.
- Hänggi MP, Teuscher UM, Roos M, et al. Long-term changes in pharyngeal airway dimensions following activator-headgear and fixed appliance treatment. *Eur J Orthod* 2008;30(6):598-605. DOI: 10.1093/ejo/cjn055.
- Kinzinger G, Czapka K, Ludwig B, et al. Effects of fixed appliances in correcting angle class II on the depth of the posterior airway space. *J Orofacial Orthop* 2011;72(4):301-320. DOI: 10.1007/s00056-011-0035-2.
- Schutz TCB, Dominguez GC, Hallinan MP, et al. Class II correction improves nocturnal breathing in adolescents. *Angle Orthod* 2011;81(2):222-228. DOI: 10.2319/052710-233.1.
- Yen-Chun Lin YC, Hsiang-Chien Lin HC, Tsai HH. Changes in the pharyngeal airway and position of the hyoid bone after treatment with a modified bionator in growing patients with retrognathia. *J Exp Clin Med* 2011;3(2):93-98. DOI: 10.1016/j.jecm.2011.02.005.
- Han S, Choi YJ, Chung CJ, et al. Long-term pharyngeal airway changes after bionator treatment in adolescents with skeletal class II malocclusions. *Korean J Orthod* 2014;44(1):13-19. DOI: 10.4041/kjod.2014.44.1.13.
- Ghodke S, Utreja AK, Singh SP, et al. Effects of twin-block appliance on the anatomy of pharyngeal airway passage (PAP) in class II malocclusion subjects. *Prog Orthod* 2014;15(1):68. DOI: 10.1186/s40510-014-0068-3.
- Jena AK, Singh SP, Utreja AK. Effectiveness of twin-block and mandibular protraction appliance-IV in the improvement of pharyngeal airway passage dimensions in class II malocclusion subjects with a retrognathic mandible. *Angle Orthod* 2013;83(4):728-734. DOI: 10.2319/083112-702.1.
- Kannan A, Sathyanarayana HP, Padmanabhan S. Effect of functional appliances on the airway dimensions in patients with skeletal class II malocclusion: a systematic review. *J Orthodont Sci* 2017;6(2):54-64. DOI: 10.4103/jos.JOS_154_16.
- Almeida FR, Lowe AA, Sung JO, et al. Long-term sequelae of oral appliance therapy in obstructive sleep apnea patients: Part 1. Cephalometric analysis. *Am J Orthod Dentofacial Orthop* 2006;129(2):195-204. DOI: 10.1016/j.ajodo.2005.10.001.

19. Battagel JM, Johal A, L'Estrange PR, et al. Changes in airway and hyoid position in response to mandibular protrusion in subjects with obstructive sleep apnoea (OSA). *Eur J Orthod* 1999;21(4):363–376. DOI: 10.1093/ejo/21.4.363.
20. Kollias I, Krogstad O. Adult craniocervical and pharyngeal changes--a longitudinal cephalometric study between 22 and 42 years of age. *Eur J Orthod* 1999;21(4):345–355. DOI: 10.1093/ejo/21.4.345.
21. Cohen AM, Vig PA. A serial growth study of the tongue and intermaxillary space. *Angle Orthod* 1976;46:332–337.
22. Poon KH, Chay SH, Choing KFW. Airway and craniofacial changes with mandibular Advancment device in chinese with obstructive sleep apnoea. *Ann Acad Med Singapore* 2008;37(8):637–644.
23. Liu Y, Zeng X, Fu M, et al. Effects of a mandibular repositioner on obstructive sleep apnea. *Am J Orthod Dentofacial Orthop* 2000;118(3):248–256. DOI: 10.1067/mod.2000.104831.
24. Doff MH, Hoekema A, Pruim GJ, et al. Effects of a mandibular advancement device on the upper airway morphology: a cephalometric analysis. *J Oral Rehabil* 2009;36(5):330–337. DOI: 10.1111/j.1365-2842.2009.01946.x.
25. Verma G, Tandon P, Nagar A, et al. Cephalometric evaluation of hyoid bone position and pharyngeal spaces following treatment with twin block appliance. *J Orthod Sci* 2012;1(3):77–82. DOI: 10.4103/2278-0203.103863.