The Hot Tooth Dilemma

Dr. Mukut Seal
Post Graduate Student

Dr. Dhanya Kumar N.M.
Professor & Head

Department of Conservative Dentistry and Endodontics

Achieving profound pulpal anesthesia is a corner stone in endodontic practice and dentistry. Profound pulpal anesthesia during the root canal procedure benefits not only the patient, for obvious reasons, but also the dentist who will be less stressed worrying about patient reactions or sudden movement during therapy. Achieving adequate anesthesia in patients can at times, be a challenge. But when one adds the condition of a "hot" tooth, the challenges increase. This article describes some strategies that the endodontist can use when treating patients with teeth having moderate-to-severe pain.

To begin, it is necessary to define what a "hot" tooth really is. The term "hot" tooth generally refers to a pulp that has been diagnosed with irreversible pulpitis, with spontaneous moderate-to-severe pain. A classic example of one type of hot tooth is a patient who is sitting in the waiting room sipping on a large glass of ice water to help control the pain. Inflammatory changes within the pulp progressively worsen as a carious lesion nears the pulp.[1] Chronic inflammation takes on an acute exacerbation with an influx of neutrophils and the release of inflammatory mediators (such as prostaglandins and interleukins) and pro-inflammatory neuropeptides[2] (such as substance P, bradykinin, and calcitonin gene-related peptide). These mediators, in turn, sensitize the peripheral nociceptors within the pulp of the affected tooth which increases pain production and neuronal excitability.[3] All of this leads to the pain that patients report as they sit in the dental chair.

In dealing with teeth diagnosed with irreversible pulpitis, determining whether adequate local anesthesia has been achieved before treatment is important. When one considers the challenges of local anesthesia in dentistry; mandibular teeth pose the most severe challenge. Mandibular anesthesia via the inferior alveolar nerve block (IANB) has traditionally been confirmed by asking the patient if their lip feels numb, probing or sticking the gingiva around the mandibular tooth to be treated or simply starting treatment and waiting for a patient response. However these techniques are not very effective in determining if pulpal anesthesia has been achieved.[4]

So why then is it so difficult to achieve adequate pulpal anesthesia in mandibular teeth even if the patient is asymptomatic? The central core theory may be the best explanation. This theory states that the outer nerves of the inferior alveolar nerve bundle supply the molar teeth whereas the nerves for the anterior teeth lie deeper. Anesthetic solutions that are currently used may not be able to diffuse into the nerve trunk to reach all the nerves and provide an adequate block which explains the difficulty in achieving successful anesthesia for mandibular anterior teeth.[3]

Patients in pain as a result of a tooth diagnosed with irreversible pulpitis have additional difficulties attaining pulpal anesthesia. One theory to explain this is that the inflamed tissue has a lowered pH which reduces the amount of the base form of the anesthetic needed to penetrate the nerve sheath and membrane. Therefore, there is less ionized form of the anesthetic within the nerve to produce anesthesia. This theory may explain only the local effects of inflammation on the nerve and not why an IANB injection is less successful when given at a distance from the area of inflammation (the hot tooth). Another theory is that the nerves arising from the inflamed tissue have altered resting potentials and reduced thresholds of excitability.[5] It was shown that anesthetic agents were not able to prevent the transmission of nerve impulses because of the lowered excitability thresholds[5] of inflamed nerves. Other theories have looked at the presence of anesthetic-resistant sodium channels[6] and the upregulation of sodium channels in pulps diagnosed with irreversible pulpitis.[7]

Objective tests can be used to better assess the level of pulpal anesthesia for all teeth. The use of an electric pulp tester (EPT) and/or the application of a cold refrigerant have been shown to accurately determine pulpal anesthesia in teeth with a normal pulp before treatment. If the patient responds negatively to the stimulus (cold or electric current), then pulpal anesthesia has been attained and the patient should not experience pain during treatment. However, in teeth diagnosed with a hot irreversible pulpitis, a failure to respond to the stimulus may not necessarily guarantee

pulpal anesthesia.[8] The patient may still report pain during treatment. Teeth with necrotic pulp chambers but whose root canals contain vital tissue may not be tested using the above means. In these cases, testing for pulpal anesthesia of the neighboring teeth may give the clinician an indication of the anesthetic status of the tooth to be treated.[8]

SUPPLEMENTAL INJECTIONS

There are several supplemental injection techniques available to help the dentist/endodontist, which are reviewed in this article. It should be reiterated that these supplemental techniques are used best after attaining a clinically successful IANB (lip numbness).

1. Intraligamentary (Periodontal Ligament) Injection:

Bangerter and colleagues reported that the periodontal ligament (PDL) supplemental injection is still one of the most widely taught and used supplemental techniques. The success of supplemental PDL injections to help achieve anesthesia for endodontic procedures has been reported to be 50% to 96%. The key to giving a successful PDL injection remains the attainment of back-pressure during the injection. Failure to get back-pressure will most likely lead to failure.[9]

PDL injections are usually given using either a standard dental anesthetic syringe or a high-pressure syringe. The development of computer-controlled anesthetic delivery systems (the Wand or the Single Tooth Anesthesia [Milestone Scientific, Livingston,NJ, USA] **(Fig 1)** devices) have been found to be able to deliver a PDL injection.

Fig. 1

2. Intraosseous Injection

The use of the intraosseous (IO) injection allows the practitioner to deliver local anesthetic solutions directly into the cancellous bone surrounding the affected tooth. There are several IO systems available in the market, including the Stabident system (Fairfax Dental Inc, Wimbledon, UK) **(Fig 2)**, X-Tip system (Dentsply, York, PA, USA) **(Fig 3)**, and


Fig. 2

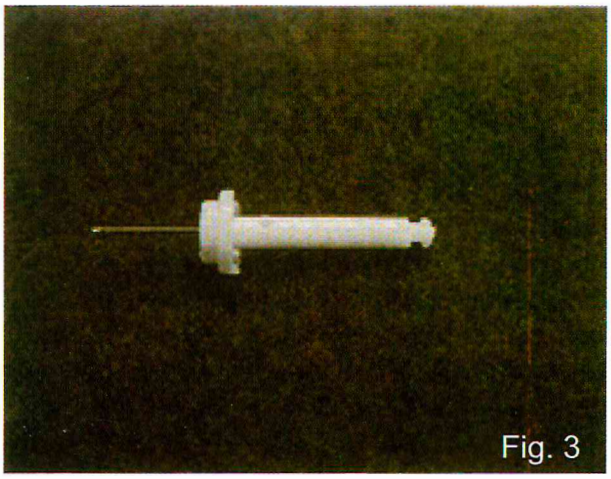
Fig. 3

IntraFlow handpiece (Pro-DexInc, Santa Ana, CA, USA).

The Stabident system consists of a 27-gauge beveled wire that is driven by a slow-speed handpiece, which perforates the cortical bone. Anesthetic solution is then delivered into the cancellous bone with a 27-gauge ultrashort needle through the perforation using a standard anesthetic syringe. The X-Tip system consists of a 2-part perforator/guide sleeve component which is also driven by a slow-speed handpiece. The perforator leads the guide sleeve through the cortical bone and then is separated from it and removed. This leaves the guide sleeve in place and allows for a 27-gauge needle to be inserted for injecting the anesthetic solution **(Fig 4)**. The guide sleeve is then removed with a hemostat at the end of the appointment.

The IntraFlow handpiece holds and drives a perforating needle and an anesthetic cartridge, which is engaged via an

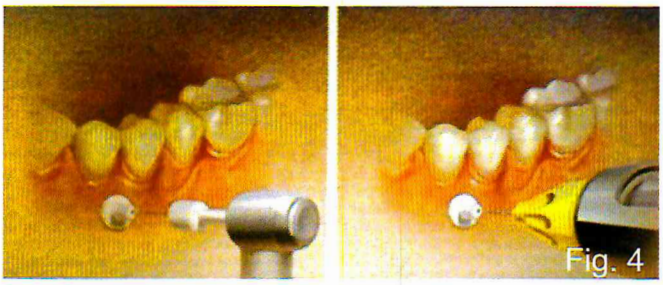

internal clutch to deliver the local anesthetic through the perforation.

One of the benefits of the IO injection is the reported immediate onset of anesthesia.[10]The injection is recommended to be given distal to the tooth to be anesthetized.[10]The exception to this rule would be the maxillary and mandibular second molars, for which a mesial site injection would be needed. The perforation site for the IO injection should be equidistant between the teeth and in the attached gingiva to allow for the perforation to be made through a minimal thickness of tissue and cortical bone and to prevent damage to the roots of the teeth.

3. Mandibular Buccal Infiltration Injection with Articaine

Recent research has looked at the use of a mandibular buccal infiltration injection of 4% articaine with 1:100,000 epinephrine as a supplemental injection to increase the success of the IANB injection. Kanaa and colleagues[11] reported a success rate of 91% (2 consecutive readings of 80 during the test period) with 4% articaine with 1:100,000 epinephrine. However, when the buccal infiltration injection was used as a supplement to the IANB in patients diagnosed with irreversible pulpitis, success was reported as only 58%. This result was much less than that attained with the IO and PDL injections.

4. Intrapulpal Injection

In approximately 5% to 10% of mandibular teeth diagnosed with irreversible pulpitis, supplemental injections (PDL and IO) do not produce adequate anesthesia even when repeated, to enter the pulp chamber painlessly. This is a prime indication that an intrapulpal injection may be necessary. The intrapulpal injection works well when it is given under back-pressure. Onset of anesthesia is immediate. Various techniques have been advocated in giving the injection; however, the key factor is giving the injection under strong back-pressure. Simply placing local anesthetic solution in the pulp chamber will not achieve adequate pulpal anesthesia.

A disadvantage of the intrapulpal injection is its short duration of action (approximately15-20 minutes). Once anesthesia is achieved, the practitioner must work quickly to remove all the tissue from the pulp chamber and the canals. The intrapulpal injection also requires that the pulp tissue be exposed to permit the injection to be given. Achieving a pulpal exposure could be very painful to the patient because the pain of treatment may begin when the dentin is exposed.[10] The injection can be very painful for the patient. The patient should be warned to expect moderate to severe pain during the initial phase of the injection.

5. Preemptive Strategies to Improve Success of the IANB Injection

Recent clinical studies have looked at the use of oral medications before treatment of a patient with a tooth diagnosed with irreversible pulpitis in the hope of improving the success rate of the IANB injection. Ianiro and colleagues used pretreatment oral doses of acetaminophen or a combination of acetaminophen and ibuprofen versus placebo in patients undergoing endodontic therapy. They reported a trend toward higher success rates (defined as no pain upon entering the pulp chamber) of 71% to 76%, respectively, as compared with placebo (46%). These differences, however, were not found to be significant. Unfortunately, follow-up studies by Agarwala and colleagues and Stein and colleagues[12] using similar doses of methylprednisolone failed to improve the success of the IANB injection.

SUMMARY

The dentist who treats patients diagnosed with a mandibular hot tooth (irreversible pulpitis) will often find achieving adequate pulpal anesthesia to be a challenge. It behooves each provider to develop a plan to deal with the eventual failures found with the IANB injection. This plan needs to include the use of supplemental anesthesia techniques. Whether the clinician's training or preference is the PDL or IO injection, these supplemental techniques have been shown to be quite effective in achieving pulpal anesthesia for teeth with irreversible pulpitis. Being able to fall back on both sets of techniques provides the dentist the confidence to provide relatively pain-free treatment for the patient having a hot tooth.

REFERENCES :

1. John M. Nusstein, Al Reader, Melissa Drum Local Anesthesia Strategies for the Patient With a "Hot"Tooth,Dent Clin N Am 54 (2010) 237247.
2. Byers MR, Na¨ rhi MV. Dental injury models: experimental tools for understanding neuroinflammatory interactions and polymodalnociceptor functions. Crit Rev Oral Biol Med 1999;10(1):439.
3. Dray A. Inflammatory mediators of pain. Br J Anaesth 1995;75(2):12531.
4. Vreeland DL, Reader A, Beck M, et al. An evaluation of volumes and concentrations Of lidocaine in human inferior alveolar nerve block. J Endod 1989;15(1):612.
5. Wallace J, Michanowicz A, Mundell R, et al. A pilot study of the clinical problem of regionally anesthetizing the pulp of an acutely inflamed mandibular molar. OralSurg Oral Med Oral Pathol 1985;59(5):51721.
6. Roy M, Narahashi T. Differential properties of tetrodotoxin-sensitive and tetrodotoxin-resistant sodium channels in rat dorsal root ganglion neurons. J Neurosci 1992;12(6):210411.
7. Sorensen H, Skidmore L, Rzasa D, et al. Comparison of pulpal sodium channel density in normal teeth to diseased teeth with severe spontaneous pain. J Endod 2004;30(4):287.
8. Hsiao-Wu GW, Susarla SM, White RR. Use of the cold test as a measure of pulpal anaesthesia during endodontic therapy: a randomized, blinded, placebocontrolled clinical trial. J Endod 2007;33(4):40610.
9. Walton R, Abbott B. Periodontal ligament injection: a clinical evaluation. J AmDent Assoc 1981;103(4):5715.
10. Nusstein J, Kennedy S, Reader A, et al. Anesthetic efficacy of the supplemental X-tip intraosseous injection in patients with irreversible pulpitis. J Endod 2003; 29(11):7248.
11. Kanaa M, Whitworth J, Corbett I, et al. Articainebuccal infiltration enhances the effectiveness of lidocaine inferior alveolar nerve block. IntEndod J 2009;42(3):23846.
12. Stein K, Reader A, Agarwala V, et al. Anesthetic effectiveness of a preemptive injection of Depo-Medrol in untreated irreversible pulpitis. J Endod 2007;33(3): 332.

ACHIEVEMENTS

Dr. Neha Mahajan

***Department of Periodontics**, won the 1st Prize for the "Best Paper" Presentation at the ICDRO World Congress held at Goa, on 15th & 16th September, 2012*