

COMPLETE DENTURE OCCLUSION- A REVIEW

Dr. Gajapathi.B PG STUDENT

DEPT. OF PROSTHODONTICS

Dr. Shashidhara.H.S. PROFESSOR

INTRODUCTION: Complete denture occlusion is the rehabilitation of mastication, phonetics and esthetics causing least or no trauma to the oral tissues.

DEFINITIONS: Occlusion: The static relationship between the incising or masticating surfaces of the maxillary or mandibular teeth or tooth analogues. GPT-8

Articulation: The static and dynamic contact relationship between the occlusal surfaces of the teeth during function. GPT-8

Balanced Articulation: The bilateral, simultaneous, anterior, and posterior occlusal contact of teeth in centric and eccentric positions. GPT-8

Lingualized Occlusion : First described by S. Howard Payne in 1941, this form of denture occlusion articulates the maxillary lingual cusps with the mandibular occlusal surfaces in centric working and nonworking mandibular positions. The term is attributed to Earl Pound. GPT-8

Linear Occlusion: The occlusal arrangement of artificial teeth, as viewed in the horizontal plane, wherein the masticatory surfaces of the mandibular posterior artificial teeth have a straight, long, narrow occlusal form resembling that of a line, usually articulating with opposing monoplane teeth. GPT-8

Occlusal rehabilitation in complete denture fall into four occlusal concepts:

- (I) BALANCED ARTICULATION
- (II) NONBALANCED ARTICULATION
- (III) LINEAR OR MONOPLANE ARTICULATION
- (IV) LINGUALIZED ARTICULATION.

The teeth molds or forms selected for developing a particular scheme and ultimately a concept were

(1) Anatomic, 2) Semi-anatomic, 3) Non-anatomic, (4) 0° teeth.

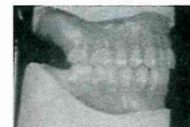
1972, Beck¹ summarized the use of these tooth forms into 10 contemporary occlusal schemes with five that demonstrated a balanced articulation concept and five that demonstrated a nonbalanced articulation.

(1) BALANCED ARTICULATION:

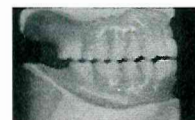
The classic example of a balanced articulation was reported by Gysi when he introduced the 33° cusp form arranged in accordance with the movements of the articulator.

With respect to anatomic teeth, the 33° cusp form was followed by a 30° posterior tooth designed and formulated by Pilkington and Turner². The 30° posterior teeth were mathematically designed and were the teeth of choice of most clinicians when developing a balanced articulation.

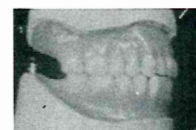The anatomic teeth are arranged in maximum intercuspation and according to a balanced articulation concept ((Pilkington-Turner vacuum fired 30° posteriors)



The anatomic teeth are arranged with buccal cusp contacts during a protrusive movement and according to a balanced articulation concept

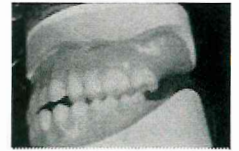

The anatomic teeth are arranged to demonstrate a right working movement according to a balanced articulation concept



C
O
D
S

The anatomic teeth are arranged to demonstrate a left balancing movement according to a balanced articulation concept



(II) NONBALANCED ARTICULATION

Sears was one of the greatest exponents of non-anatomic tooth forms arranged to a nonbalanced articulation. Pound advocated a non balanced articulation that stresses the position of the anterior teeth and was developed to preserve the phonetic values of the patient in harmony with increased denture stability and efficiency in the chewing cycle.

(III) LINEAR OR MONOPLANE ARTICULATION

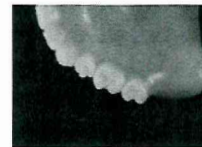Jones advocated monoplanar articulation in 1972. In this concept, a non-anatomic occlusal scheme is used with a few specific modifications. The first departure is the articulator used. It should accommodate large casts, it should not show lost motion, and it should possess an incisal guide pin. Another departure is the arrangement of maxillary and mandibular teeth without any vertical overlap. The amount of horizontal overlap is determined by the jaw relationships. The maxillary posterior teeth are set first, and the occlusal plane must fulfill certain requirements.

- ★ The occlusal plane should evenly divide the space between the upper and lower ridges.
- ★ The occlusal plane should parallel the mean denture base foundation.
- ★ Finally, the plane should fall at the junction of the upper and middle thirds of the retromolar pads.

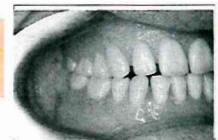
In the final arrangement of the teeth the maxillary and mandibular teeth, except for the second molars, are in contact from anterior to posterior in maximum intercuspation. The occlusal surface of the upper second molar but 2mm above the occlusal plane, thus well out of occlusion. This condition is established because the first and second premolars and the first molars masticate the food. The second molars are space fillers and do not function. With the introduction of 0° teeth, the monoplanar scheme has been used extensively in developing the occlusion for patients requiring a complete denture.

The posterior teeth are positioned on a flat plane. The anterior teeth are positioned with a horizontal and vertical overlap, and the emphasis in tooth arrangement is to establish maximal tooth contact in the centric jaw relation position. Simultaneous tooth contacts in lateral and protrusive excursion are not a point of emphasis. Developing a curved occlusal plane anteroposteriorly and mediolaterally during tooth arrangement can also result in a balanced articulation when using 0° teeth.

0° Non-anatomic teeth arranged to a nonbalanced articulation concept



0° Non-anatomic teeth arranged with anteroposterior and mediolateral compensating curves demonstrating a balanced articulation concept.



DISADVANTAGES:

- ★ Flat premolars may appear less esthetic
- ★ Reported as less efficient in chewing tests
- ★ Anterior esthetics need more overjet and no overbite

(IV) LINGUALIZED ARTICULATION

In 1927, Gysi introduced the concept of lingualized articulation

In 1941, Payne reported on Farmer's posterior setup that used 30° cusp teeth that were selectively reshaped to fulfill the concept of lingualized articulation and meet the individual requirements of edentulous patients.

Murrell described lingualized articulation as an approach to achieving success for patients with difficult lower ridges and reported that patients experienced greater chewing efficiency with this occlusal scheme.

Most of these schemes have involved a combination of specific tooth molds for the maxillary and mandibular arches that were not necessarily developed for this articulation.



Combinations of tooth forms that have been successfully used to establish the lingualized articulation concept include the maxillary Trubyte Functional mold and the mandibular 0°

More recently, tooth manufacturers have specifically developed tooth molds for lingualized articulation

Combinations of tooth forms that have been successfully used to establish the lingualized articulation concept include the maxillary Trubyte Anatoline mold and the mandibular Monoline mold

The MLI tooth molds were designed for lingualized articulation. The maxillary tooth is anatomic in form with excellent cusp heights for maximum lingual cusp contact with the mandibular antagonist

The cusp heights of the MLI mandibular tooth mold are low and allow good maxillary lingual cusp contact and freedom in eccentric movements.

The Ortholingual maxillary and mandibular tooth molds were created specifically for the lingualized articulation concept

The Molds For Lingualized Articulation: Lingualized articulation is based on the maxillary lingual cusp functioning as the main supporting cusp in harmony with the occlusal surfaces of the lower teeth. The maxillary teeth are usually more anatomic in appearance with greater cusp height.

Lingualized articulation is based on the maxillary lingual cusp functioning as the main supporting cusp in harmony with the occlusal surfaces of the lower teeth. The maxillary teeth are usually more anatomic in appearance with greater cusp height.

The occlusal morphology of the mandibular teeth is usually uncomplicated but provides the opportunity for interdigitation with the lingual cusps of the maxillary teeth.

Anterior and posterior reference points

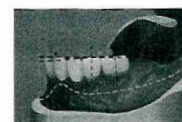
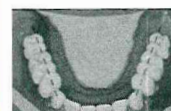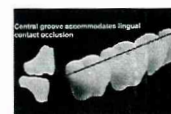
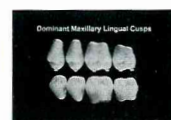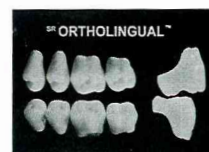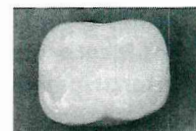

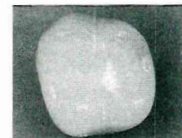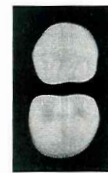A line drawn from the tips of the mandibular anterior teeth and connecting with a point 1 to 2 mm below the top of the retromolar pad establishes the plane of occlusion and serves as the starting point for the anteroposterior compensatory curve.

Buccolingual positioning of the teeth

The width of the first and second mandibular molars necessitates positioning the central groove of these teeth slightly to the buccal of a line connecting the tip of the canines with a point in the middle of the retromolar pads. This positioning allows space for the tongue and avoids crowding this important anatomic structure during speech and mastication

Anteroposterior compensatory curve

The anteroposterior compensatory curve is established to enhance balanced articulation along the protrusive pathway. The curve begins with the first premolar, and the first and second molars are slightly elevated above the plane of occlusion



C
O
D
S

Mediolateral compensatory curve:

The mediolateral compensatory curve is a subtle curve that usually does not exceed 5° to 10° above the horizontal plane of occlusion

It is important to achieve maximum interdigitation of the maxillary teeth in the central groove of the mandibular antagonists in the arrangement of the lingualized articulation scheme to establish the maxillary lingual cusps as the main supporting cusp.

After the clinical remount of the maxillary and mandibular prostheses, small strips of articulating paper should be interposed on both sides of the mandibular arch. With the articulator locked in the hinged position, all occlusal prematurities should be marked.

Tooth structure should be removed in all areas of contact using carbide trimming and finishing bur #7010 except the maxillary lingual cusp. Premature contacts are most often at the central fossa or marginal ridges of the lower teeth and on the lingual incline of the maxillary facial cusp. The contacts should be marked and the teeth reshaped until all lingual cusps in the maxillary posterior teeth demonstrate maximal intercuspation with their mandibular antagonists.

Solid contact between the maxillary lingual cusps and the mandibular central groove is accomplished with a minimum of adjustment.

The prostheses are returned to the mouth after the occlusal reshaping procedures to verify that maximal intercuspation has been achieved at the centric jaw relation position.

Maximum intercuspation is verified in the oral environment following the occlusal reshaping procedures.

Premature cross-arch balancing contacts on the lingual inclines of the mandibular facial cusps must be reduced to provide freedom of movement on the contralateral working cusps.

Smooth, free-gliding articulation must be observed in lateral excursions. The working movement should demonstrate light contact between the maxillary buccal cusps with the mandibular buccal cusps in the lingualized articulation concept.

On the balancing side the maxillary lingual cusps should glide smoothly over the lingual inclines of the mandibular buccal cusps in the lingualized articulation concept.

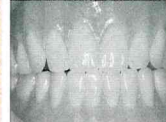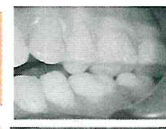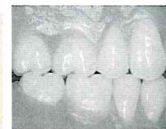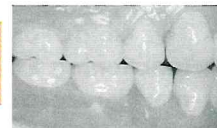
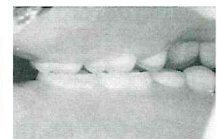
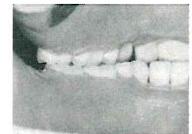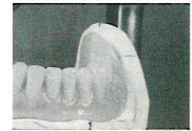
In a protrusive movement in lingualized articulation, the maxillary anterior teeth should demonstrate only light contact with the anterior mandibular teeth. The maxillary posterior teeth in contact with the mandibular posterior should not occlude the anterior teeth.

The occlusion is also examined for an absence of interference during mandibular movements. With lingualized articulation using the tooth molds previously discussed, these criteria are easily met.

SUMMARY: Lingualized articulation has been advocated by many practitioners. It can be achieved using a variety of tooth molds arranged in a number of ways that seem to provide the least complicated approach to occlusal rehabilitation and to satisfy the needs of the edentulous patient. The different combinations of tooth molds available from one particular tooth manufacturer, and now specific molds designed for lingualized articulation by other manufacturers, allows the practitioner to improve the likelihood of maximal intercuspation, avoid defective occlusal contacts, determine cusp height for selective occlusal reshaping, and achieve a natural and pleasing appearance. The articulation and arrangement of the posterior teeth in lingualized articulation assures a standardized arrangement.

Reference:

- [1] Beck HO. Occlusion as related to complete removable prosthodontics. J Prosthet Dent 1972;27:246-56.
- [2] The new Pilkington-Turner vacuum fired 30 degree posteriors. York (PA): Dentists' Supply Company of New York; 1953.p.48.



C

O

D

S

