

# Prosthodontics A Series Of Case Reports



Dr. (Brig) Xavier Mathew  
Professor & Head



Dr. Vinay Kumar  
Professor



Dr. Virendra Singh  
Post Graduate Student

Dept. of Prosthodontics, College of Dental Sciences, Davangere.

## Case 1: Maxillary Obturator

A female patient Name Padma, Age : 27 years, (OPD No. 51925) reported to department of Prosthodontics on 18/8/08 after maxillectomy for obturator. She gave a history of surgery on right side of upper jaw, 7 days back.

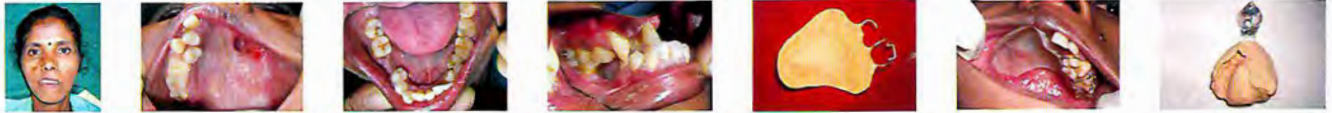

Fig-1 to 4 Pre Treatment

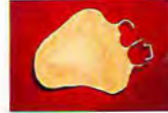

Fig-5 Intermediate Obturator

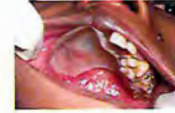

Fig-6 & Fig-7 Primary Impression

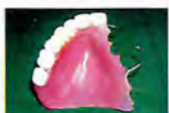

Fig-8 Final Prosthesis



Fig-9 Custom Tray



Fig-10 Secondary Impression

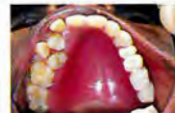

Fig-11 to 13 Final Prosthesis Insertion

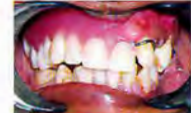
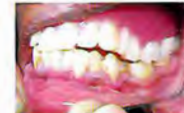
Fig-14 Post Treatment

On intra oral examination partially edentulous maxillary arch with two oronasal fistulae were observed. Patient was given an interim obturator on the same day and was recalled after one month for evaluation of tissue response and fabrication of definitive obturator. Definitive obturator was fabricated similar to conventional obturator and inserted on 16/9/2008. (Fig-1-14)

## Case 2: Ocular Prosthesis

A female patient Name: Jayalakshmi, Age : 11 years, (OPD No. 4321) reported to the department of Prosthodontics, CODS, Davangere on 6/12/07 with a chief complaint of poor appearance due to missing right eye. On examination found that right eye globe was missing with adequate space for fabrication of ocular prosthesis. It was planned to restore the defect with custom made ocular prosthesis.

Step in fabrications :

1. Rubber base internal surface and alginate external surface impression was made.
2. Two piece cast was formed.
3. Wax pattern tried in defect.
4. Wax pattern flaked, dewaxed and acrylised with white heat cure resin.
5. Photo iris pasted after try in and characterization was done.
6. Inserted in eye defect and post insertion instruction were given on 13/11/07. (Fig-1-8)



Fig. 1



Fig. 2

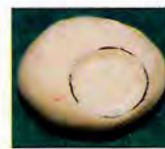

Fig. 3



Fig. 4




Fig. 5

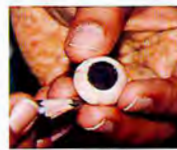

Fig. 6

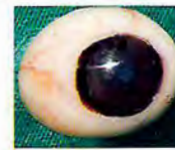

Fig. 7



Fig. 8

## Case 3: MAXILLARY HOLLOW BULB OBTURATOR

A male patient Name : Suresh, Age : 56 years, (OPD No. 45053) reported to department of Prosthodontics on 18/8/08 with chief complaint of difficulty in eating due to loss of all teeth. Oral examination revealed edentulous maxillary and mandibular arch with a large cleft extending from alveolar process till the soft palate (Veau's class III cleft). It was planned to fabricate a hollow bulb obturator with denture for maxillary arch and conventional denture for mandibular arch. 1. Patient was recalled for follow up every month and was happy with masticatory efficiency and improved quality of speech. (Fig-1-17)

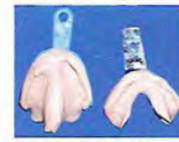
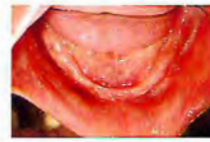
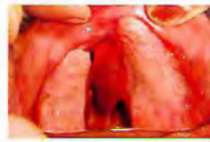Fig-1 to 3 Pre Treatment

Fig-4 Primary Impressions Fig-5 Diagnostic Casts

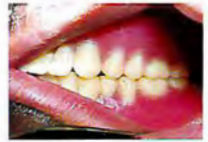
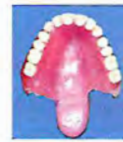
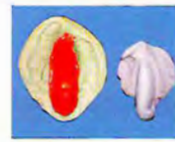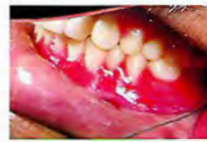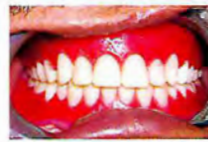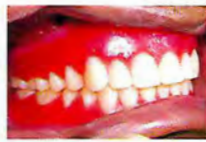Fig-6 Final Impression

Fig-7 to 9 Wax Try In

Fig-10 to 12 Final Prosthesis

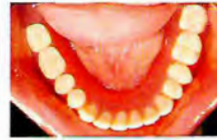
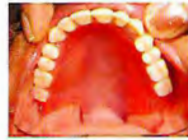
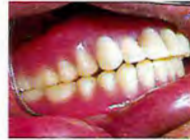Fig-13 to 16 Final Prosthesis Insertion

Fig-17 Post Treatment

## Case 4: PORCELAIN LAMINATES

A female patient Name : Khusboo, Age : 18 years, (OPD No. 5705) reported to department of Prosthodontics on 18/8/08 with chief complaint of discoloured anterior teeth. It was diagnosed as enamel hyperplasia due to hyperfluorosis. It was planned to fabricate porcelain laminates on 13 to 23.

Steps :

1. Minimal tooth reduction (0.3 to 0.5 mm) was done for laminates
2. Gingival retraction and impression made with rubber base material.
3. Two casts obtained - i) Master cast ii) Refractory cast.
4. Laminates were fabricated on refractory cast and marginal fit checked on master cast.
5. Try in done and finally cemented to prepared teeth using resin cement on 23/9/2008. (Fig1-11)

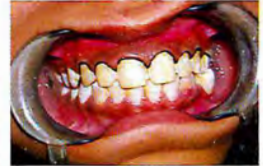
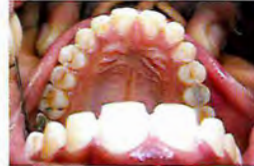
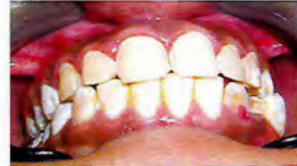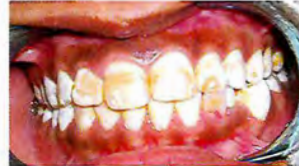Fig-1 & Fig-2 Pre Treatment

Fig-3 & Fig-4 Tooth Preparation

Fig-5 Gingival Retraction

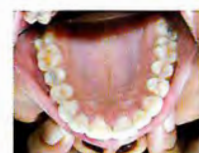
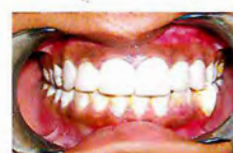
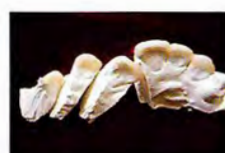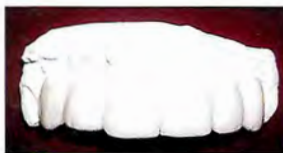Fig-6 Ceramic Buildup

Fig-7 & Fig-8 Final Prosthesis

Fig-9 & Fig-10 Final Prosthesis Cemented

Fig-11 Post Treatment

## Auricular Prosthesis

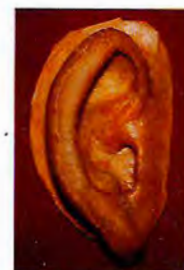
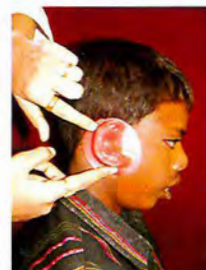
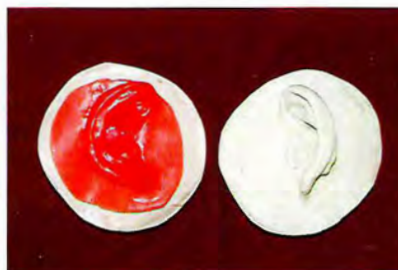Fig. 1

Fig. 2

Fig. 3

Fig. 4

Fig. 5